

Bilateral dysfunction of superior laryngeal nerves as a consequence of cervical necrotising fasciitis

Obojestranska disfunkcija zgornjih grlnih živcev kot posledica cervikalnega nekrozantnega fasciitisa

Robert Šifrer, Iztok Fošnarič, Katja Rainer, Jure Urbančič, Aleš Grošelj, Miha Žargi

University Department of Otorhinolaryngology and Head & Neck Surgery Ljubljana, UKC Ljubljana, Slovenija

Korespondenca/ Correspondence:

asist. Robert Šifrer dr. med.
e: robert_sifrer@hotmail.com

Ključne besede:

cervikalni nekrozantni fasciitis; disfagija; toksični nevritis; disfunkcija možganskih živcev; zgornji grlni živec

Key words:

cervical necrotizing fasciitis; dysphagia; toxic neuritis; cranial nerve dysfunction; superior laryngeal nerve

Citirajte kot/Cite as:

Zdrav Vestn 2015; 84: 701–6

Prispelo: 2. sept. 2014,
Sprejeto: 4. feb. 2015

Izveček

Izhodišča: Cervikalni nekrozantni fasciitis je infekcijska bolezen z resnimi zapleti in slabo napovedjo izida. Poročamo o primeru cervikalnega nekrozantnega fasciitisa, ki je povzročil obojestransko disfunkcijo zgornjih grlnih živcev, in opisujemo značilnosti tega redkega zapleta.

Prikaz primera: 71-letna bolnica s cervikalnim nekrozantnim fasciitisom je po operaciji dobila težave z disfagijo. Radiološka in fiberoptična obravnava sta pokazali aspiriranje in hiposenzibiliteto glotisa in supraglotisa. Poleg nezadostnega dviga grla pojasnjujemo disfagijo še s senzoričnim deficitom supraglotisne sluznice, ki mu sledi odsotnost addukcije glasilk med požiranjem. Senzorični deficit smo pripisali toksičnemu nevritisu, ki je povzročil disfunkcijo obeh notranjih vej zgornjih laringealnih živcev. Ozdravitev cervikalnega nekrozantnega fasciitisa in toksičnega nevritisa sta omogočila povrnitev senzorične funkcije in požiranja.

Zaključki: Čprav literatura o tem poroča le občasno, so bolniki s cervikalnim nekrozantnim fasciitisom nagnjeni k toksičnemu nevritisu in zato nevrološkim izpadom možganskih živcev. Sodijo k dodatnim zapletom te bolezni.

Abstract

Background: Cervical necrotizing fasciitis is an infectious disease with serious complications and grave prognosis. We report a case of cervical necrotizing fasciitis with consequent bilateral dysfunction of the superior laryngeal nerves and describe the characteristics of this exceptional complication.

Case report: A 71-year-old female patient, surgically treated for cervical necrotizing fasciitis, suffered from severe dysphagia after surgery. Radiographic and fiberoendoscopic evaluation showed aspiration and hyposensibility of glottis and supraglottis. Apart from inadequate laryngeal elevation, we explain dysphagia also by sensory deficit of the supraglottic mucosa with consequent lack of vocal folds adduction during swallowing. The sensory deficit was attributed to the toxic neuritis-mediated dysfunction of both internal branches of the superior laryngeal nerves. The healing of both cervical necrotizing fasciitis and toxic neuritis led to the restoration of sensory function and swallowing.

Conclusions: Although only occasionally reported in the literature, patients with cervical necrotizing fasciitis are prone to toxic neuritis-mediated neurological deficits of the cranial nerves, which are considered to be another complication of this entity.

Introduction

Necrotizing fasciitis (NF) is a life-threatening, rapidly-spreading soft tissue infection^{1,2} that causes progressive necrosis of deep fasciae, leading to necrosis of neighbouring soft tissues.³ The head and neck are involved in 2.6 % of cases.^{4,5} According to Krenk,⁶ Wolf² and Lanišnik⁷, the incidence

of cervical NF (CNF) is 0.0001–0.0002. It can be either idiopathic or secondary;⁴ in the latter case, it is caused by infections, trauma or surgery.²

The infection process begins 48 hours after an initial insult.⁸ Early clinical signs and symptoms are nonspecific.⁴ Initially, there is

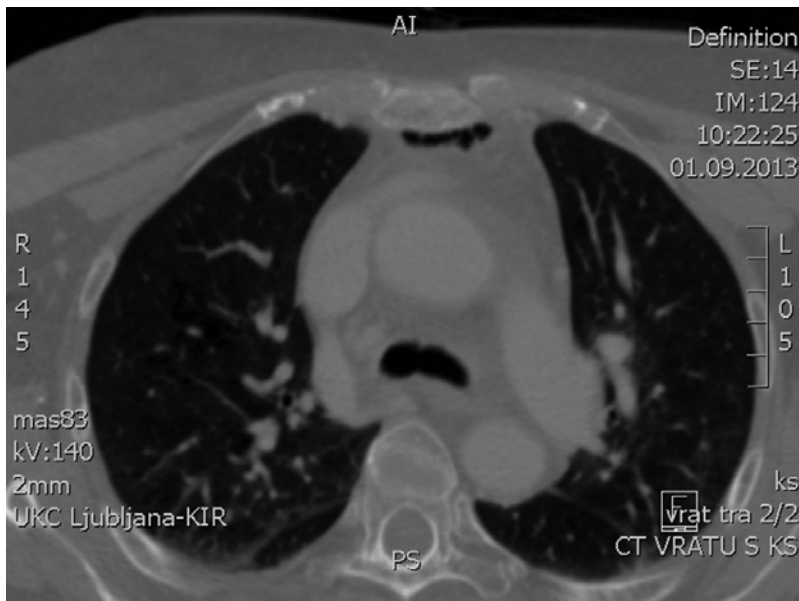
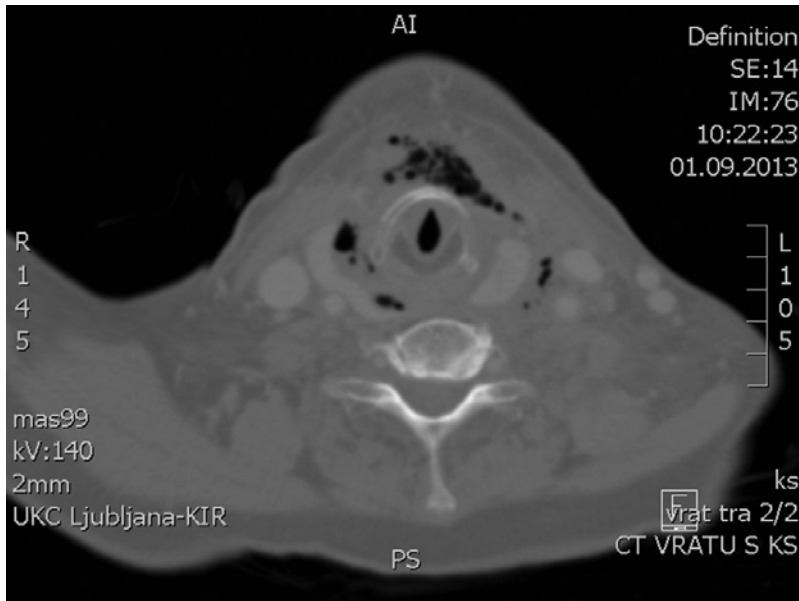


Figure 1: Axial CT image of the neck demonstrating fluid and gas collections, thickening of the subcutaneous tissues and cervical muscles, and signs of soft tissue dissection at the level of thyroid cartilage.

Figure 2: Axial CT image of the thorax demonstrating an extension of gas collections in the mediastinum at the level of tracheal carina.

a patchy,⁶ smooth,⁹ shiny¹⁰ erythema of the cervical skin, without sharp demarcation from uninvolved skin.⁹ It is accompanied by edema, crepitation, tenderness, pain on palpation² and fever.⁶ The pain is more severe than expected,⁴ and may be felt deep in the muscles¹¹, but the affected skin area may also be insensitive.¹² Later on, the skin becomes dusky, covered with blisters and bullae and finally necrotises.⁴ If left untreated, the skin breaks down and copious purulent debris and “dishwater” fluid ensue.¹ The sepsis develops within 48 hours of symptom onset.²

Laboratory tests show a very rapid rise of CRP values⁴ and leukocytosis with a left

shift.⁸ The CT scan of the neck and chest shows specific signs indicating the CNF and its extent, and offers anatomic information necessary for surgical planning.¹⁰ CT findings predicting CNF include diffuse thickening of the skin, subcutaneous tissues, fasciae and muscles, fluid and gas collections^{8,13} and fascial plane blunting or dissection.¹ The presence of gas within the soft tissues in the absence of previous surgery, radiotherapy¹⁴ or trauma is a pathognomonic sign. In edentulous patients, CT scan can also establish eventual odontogenic origin of infection. In dentate patients with dental fillings, however, panoramic radiograph of the mandible is additionally recommended, due to artefacts on the CT scan. Another diagnostic option is surgical approach, i.e. a 2-cm-long neck incision through the platysma. If loose tissue planes, friable muscles,¹ murky dish-water discharge, minimal resistance after finger insertion and no bleeding are found, the CNF is diagnosed.⁸

Intravenous broad-spectrum antibiotics should be given in high doses.⁴ Initially, an antibiotic effective against aerobic and anaerobic bacteria infection is prescribed. Later on, the therapy should be targeted against the microorganisms isolated from the microbiological samples.⁸ Nutritional, hemodynamic and intensive care supportive measures are vital.^{4,7} Surgical treatment is the key intervention. The excision and debridement must be quick and substantial⁶ in order to decrease the bacterial load,² halt both the release of inflammatory mediators and the spread of necrotizing process.^{4,8} The excision with fasciotomy should be continued until the tissues bleeding freely on incision are encountered.⁴ Two adjunctive treatment modalities that could theoretically reduce necrosis development⁶ are intravenous Immunoglobulin Gamma and Hyperbaric Oxygenation.^{8,10}

The prognosis of CNF is grave as dangerous complications may appear in a matter of days leading to descending necrotizing mediastinitis, multi-organ failure, septic shock and death. The lesion of the cranial nerves as a complication of CNF has only occasionally been reported in the literature. Cutilli¹⁵ and Chueng¹² stated CNF can extend into

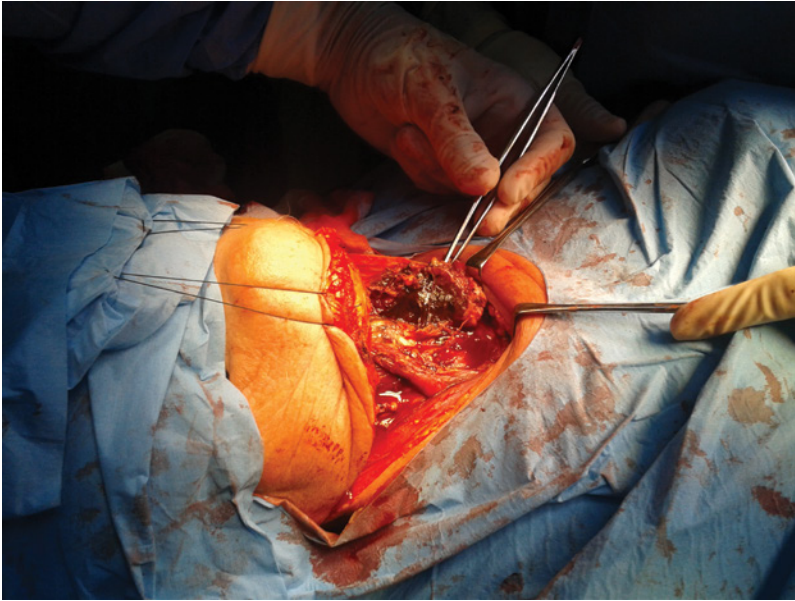


Figure 3: Necrosis of the prelaryngeal muscles as seen during surgery.

the surrounding nerves. Wolf² reported the neural deficits of the accessory nerve, hypoglossal nerve and of marginal branch of the facial nerve in 35 %. Lanišnik⁷ reported partial facial nerve palsy in 33 %. To the best of our knowledge, the dysfunction of the superior laryngeal nerve from CNF has not yet been reported.

Case report

A 71-year-old edentulous female with arterial hypertension and diabetes mellitus type II suffered from two-day-long dysphagia, odynophagia and hoarseness without fever. The transnasal flexible endoscopy revealed normal mobility of the larynx with barely notable mucosal swelling of the retrocricoid area and both piriform sinuses, and copious accumulation of the saliva in the hypopharynx. There were erythema, soft swelling and crepitations present over the prelaryngeal skin and the upper chest. It was excruciatingly tender to palpation.

The laboratory blood tests showed leucocytosis ($18.52 \times 10^9/L$) with left shift neutrophilia ($16.12 \times 10^9/L$), elevated CRP (330 mg/L) and procalcitonine levels (9.85 mg/L). An urgent CT scan of the neck and chest showed some fluid collections and widely spread collections of gas, thickening of the subcutaneous tissues and cervical muscles, and signs of soft tissue dissection, which is characteristic for CNF (Fig.

1). Moreover, the gas collections and minor streaks of fluid collections were also seen in the anterior mediastinum all the way to the tracheal carina, i.e. signs of descending mediastinitis (Fig. 2). No further diagnostics was performed. Empiric intravenous antibiotic therapy with amoxicillin-clavulanic acid and metronidazole was started immediately.

Based on the clinical signs, the radiological findings and the laboratory test results, NF was diagnosed and a surgical procedure under general anaesthesia was planned. The transverse collar incision was carried out and a skin flap in the subplatysmal plane was elevated. Dirty brown-black dishwater and a typical foul odour were noted. The subplatysmal fatty tissue, the prelaryngeal muscles, the superficial part of the thyroid gland, the lymph nodes and fatty tissue of nodal levels III and IV in the left, the parts of the left scalmi muscles had already necrotized (Fig. 3). All necrotic tissues were removed until freshly bleeding tissue was reached. Drains were placed into the parapharyngeal, retropharyngeal and the left pterygoid spaces and a transcervical digital mediastinotomy was performed. Malodorous brown-black dishwater again poured out of all aforementioned neck spaces and the mediastinum. The microbiologic samples and a biopsy of the affected tissue were taken. At the end of the procedure, direct laryngoscopy and tracheostomy were performed and a nasogastric feeding tube was inserted. Even after extensive discussion with the patient and her relatives the origin of CNF could not be found.

The microbiological culture from the wound smear obtained during the surgery revealed the following microorganisms: *Streptococcus constellatus ssp. constellatus*, *Lecleria adecarboxylata*, *Lactobacillus catenaformis*, *Prevotella intermedia*, *Prevotella buccae* and *Parvimonas (Micromonas) micro*. According to this finding and the sensitivity of microorganisms, we changed the antibiotics for intravenous clindamycin and cefotaxime. The histological finding of the biopsy confirmed our clinical suspicion of NF.

After the surgical procedure, the patient's voice became breathy due to inadequate

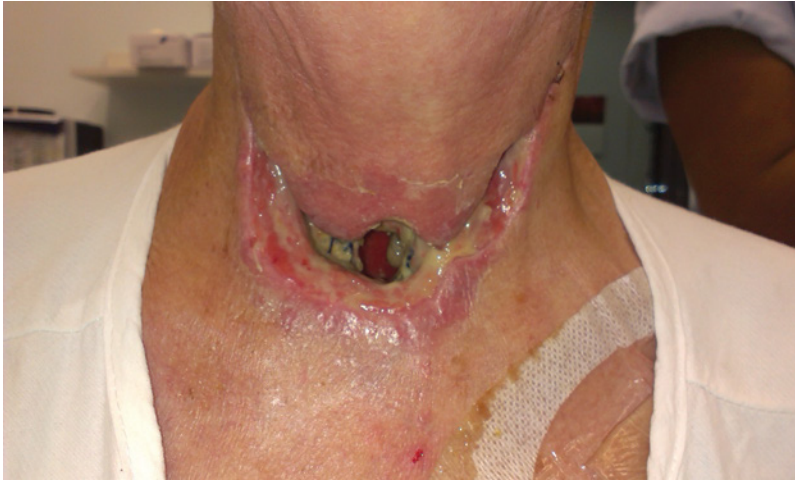
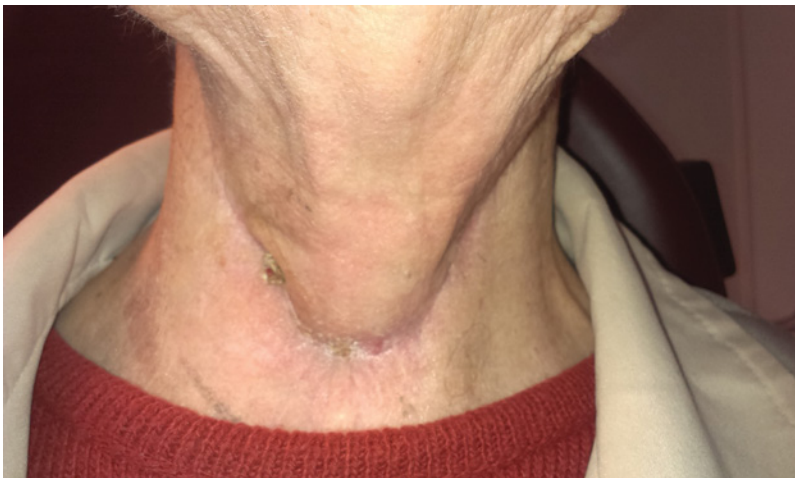
Figure 4: Slow healing of the surgical neck wound on the 12th postoperative day.

glottic closure. In a few weeks, her voice became normal. However, several serious complications, such as slow healing of the neck wound (Fig. 4), pleural effusion, pneumonia, acute renal failure, septic shock, depression and dysphagia occurred. All of them, except the dysphagia, resolved within four weeks of intensive medical treatment, supportive measures and rigorous daily wound care (Fig. 5).

The time from CNF surgery and tracheostomy to decannulation was 40 days. Subsequent fiberoendoscopic evaluation of swallowing showed that there was a massive spillage of liquids and semiliquids over the aryepiglottic folds and posterior commissure into the larynx (Fig. 6). The coughing reflex appeared when the bolus passed the larynx and entered the trachea. Rough sensibility testing with the tip of the instruments, e.g. touch of the aryepiglottic folds and the glottis, showed marked hyposensibility, i.e. no

Figure 5: The patient's neck with the surgical wound healed two and a half months after surgery.



laryngeal adductor reflex was elicited. On gross observation, there were neither laryngeal elevation, nor closure of the laryngeal entrance by the epiglottis or adduction of the vocal folds during swallowing.

Radiographic and repeated fiberoendoscopic evaluations of the upper airway tract during swallowing showed massive aspiration (Fig. 6). The patient was discharged from the hospital seven weeks after surgery with a gastrostomy feeding tube but without tracheostomy.

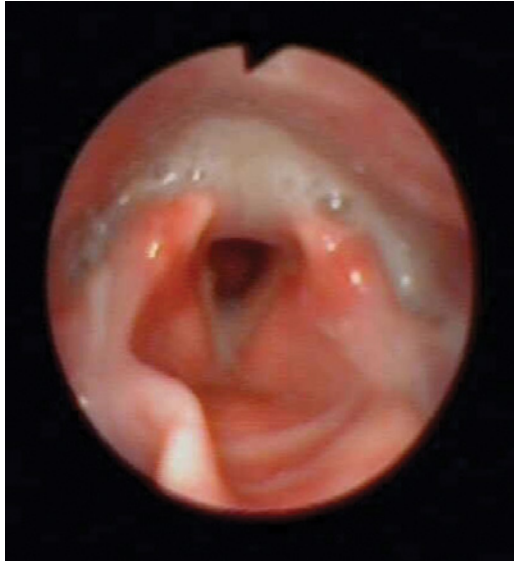Two-and-a-half months after surgery, the patient spontaneously started to swallow without aspiration, prompting us to remove the gastrostomy tube. The glottic closure was complete on examination.

Discussion

In this report, we have described a unique case of severe dysphagia with aspiration in a patient with CNF. Considering the reasons for dysphagia in our patient, several aspects should be emphasized. Firstly, the prelaryngeal muscle removal during surgery resulted in both the inadequate laryngeal elevation and, consequently, the lack of passive closure of its entrance by the epiglottis. Secondly, there was the sensory deficit of the supraglottic mucosa. It was discovered by touching the supraglottic mucosa bilaterally with the tip of the endoscope, which failed to elicit the reflexive adduction of the vocal folds. Therefore, there was no airway protection during swallowing. Considering both normal movement of the vocal cords during phonation and breathing and evident sensory deficit of the supraglottic mucosa, we concluded that the lack of vocal cords adduction during swallowing with consequent aspiration was attributable to the dysfunction of both internal branches of the superior laryngeal nerves.

The internal branches of the superior laryngeal nerves carry the sensory impulses from the laryngeal mucosa down to the vocal cords. They enter the larynx through the thyrohyoid membrane that is situated posteriorly and in close proximity to the prelaryngeal muscles that were most severely affected by CNF. Therefore, the paralysis of

Figure 6: Fiberendoscopic evaluation of swallowing shows a spillage of liquids over the aryepiglottic fold and posterior commissure into the larynx.



both nerves was the result of the release of the toxins from NF leading to toxic neuritis. Although the nerves are quite resistant to inflammation, we suppose that in the case of a fulminant neck inflammation (such as CNF) the cranial nerves may very rapidly become infiltrated by inflammatory mediators and toxins, which is not the case in less acute forms of inflammation. Eventually, both CNF and toxic neuritis of the superior laryngeal nerves healed. As the sensory function restored and the patient adapted to the new situation after surgery, swallowing finally returned to normal.

The dysfunction of other cranial nerves after CNF, i.e. accessory nerves, hypoglossal nerves and facial nerves, have already been reported, but only by few authors.^{2,7} Nevertheless, this supports our thesis that CNF can affect the surrounding cranial nerves and that the involvement of a particular nerve depends on the location and severity of CNF.

Conclusion

Our case clearly shows that patients with CNF are prone to toxic neuritis-mediated neurological deficits of the cranial nerves, which are considered to be another complication of CNF in addition to those already known. Unless they are recognized and dealt with immediately, further complications follow. In the case of dysfunction of the superior laryngeal nerves, the principal complication is dysphagia leading to aspiration pneumonia, dehydration and cachexia.

Acknowledgements

The authors would like to thank Prof. Irena Hočevnar-Boltežar, MD, PhD for the fiberendoscopic evaluation of swallowing of the patient and for all advices on this article. Our thanks go also to Miha Rainer for his help at editing the photos.

References

1. Lee Jw, Immerman SB, Morris LGT. Techniques for early diagnosis and management of cervicofacial necrotising fasciitis. *J Laryngol Otol* 2010; 124: 759–764.
2. Wolf H, Rusan M, Lambertsen K, Ovesen T. Necrotizing fasciitis of the head and neck. *Head Neck* 2010; 32: 1592–1596.
3. Gündeşlioğlu AÖ, Ozen EÇ. Necrotizing fasciitis of the cervical region following extravasation injury. *Case Rep Med* 2012; Article ID 941578.
4. Malik V, Gadepalli C, Agrawal S, Inkster C, Lobo C. An algorithm for early diagnosis of cervicofacial necrotizing fasciitis. *Eur Arch Otorhinolaryngol* 2010; 267: 1169–1177.
5. Hohlweg-Majert B, Weyer N, Metzger MC, Schön R. Cervicofacial necrotizing fasciitis. *Diabetes Res Clin Pract* 2010; 72: 206–208.
6. Krenk L, Nielsen HU, Christensen ME. Necrotizing fasciitis in the head and neck region: an analysis of standard treatment effectiveness. *Eur Arch Otorhinolaryngol* 2007; 264: 917–922.
7. Lanišnik B, Čizmarević B. Necrotizing fasciitis of the head and neck: 34 cases of a single institution experience. *Eur Arch Otorhinolaryngol* 2010; 267: 415–421.
8. Oguz H, Yilmaz MS. Diagnosis and management of necrotizing fasciitis of head and neck. *Curr Infect Dis Rep* 2012; 14: 161–165.
9. Sasindran V, Joseph A. Necrotizing fasciitis: an unusual presentation. *Indian J Otolaryngol Head Neck Surg* 2011; 63: 390–392.
10. Skitarelić N, Mladina R, Morović M, Skitarelić N. Cervical necrotizing fasciitis: sources and outcomes. *Infection* 2003; 31: 39–44.
11. Tomažič J, Volčanšek G. Medical history and examinations of adult patients with infectious disease. *Med Razg* 2009; 48: 397–410.
12. Chueng K, Clinkard DJ, Enepekides D, Peerbaye Y, Lin VY. An Unusual Presentation of Ludwig's Angina Complicated by Cervical Necrotizing Fasciitis: A Case Report and Review of the Literature. *Case Rep Otolaryngol* 2012; Article ID 931350.

13. Becker M, Zbären P, Hermans R, Becker CD, Marchal F, Kurt AM, Marré S, Rüfenacht DA, Terrier F. Necrotizing fasciitis of the head and neck: role of CT in diagnosis and management. *Radiology* 1997; 202: 471–476.
14. Bou-Assaly W, McKellop J, Mukherji S. Computed tomography imaging of acute neck inflammatory processes. *World J Radio* 2010; 2: 91–96.
15. Cutilli T, Cargini P, Placidi D, Corbacelli A. Necrotizing fasciitis of the maxillofacial region caused by dental infection. A case report and review. *Minerva Stomatol* 2007; 56: 469–476.