

Rib cage deformity during two-stage tissue expander breast reconstruction in a patient with previous radiotherapy: A case report

Deformacija prsnega koša pri dvostopenjski rekonstrukciji dojke s tkivnim razširjevalcem pri bolnici po radioterapiji: Prikaz primera

Aleš Porčnik, Uroš Ahčan

Department of Plastic, Reconstructive and Aesthetic Surgery and Burn Unit, University Clinical Centre Ljubljana, 1525 Ljubljana, Slovenia

Korespondenca/

Correspondence:

Uroš Ahčan, MD, PhD, professor, Head of Department, Department of Plastic, Reconstructive and Aesthetic Surgery and Burns Unit, University Clinical Centre Ljubljana, Zaloška cesta 2, 1525 Ljubljana, Slovenia, e: uros.ahcan@kclj.si

Ključne besede:

radioterapija; deformacija prsnega koša; tkivni razširjevalec; računalniška tomografija

Key words:

radiotherapy; rib cage deformity; tissue expander; CT scan

Citirajte kot/Cite as:

Zdrav Vestn 2016; 85: 56–65

Prispelo: 19. dec. 2014, Sprejeto: 19. maj 2015

Abstract

Background: Two-stage tissue expander breast reconstruction in irradiated breast is known to have high complication rates. Hardened overlying soft tissues and weakened underlying ribs enable the expander to protrude also in the posterior direction, increasing possibilities of rib cage deformity.

Case report: We present a case of a 40 year-old woman who underwent a secondary breast reconstruction of previously irradiated right breast and primary reconstruction of her left breast, both with a two-stage tissue expander breast reconstruction technique. Her 1st operation and the post-operative recovery were uneventful. After multiple expander fillings, final volume in her left and right expander reached 260 ml and 400 ml. During her 2nd operation surgeon noticed a prominent concave rib cage depression of her 4th and 5th right ribs, including signs of an old 4th rib fracture. Due to a large volume deficit, a bigger final implant with a greater projection was inserted to achieve the desired shape and symmetry of both breasts.

Conclusion: Patients undergoing two-stage breast reconstruction with tissue expander and a history of previous irradiation are predisposed to a various chest-wall deformities more than non-irradiated patients. If chest-wall depression with/without rib fracture is found intra-operatively, a bigger implant should be used together with a subsequent radiological evaluation. In the future, the development of a new, modified expander with a harder base could minimise such complications.

Izvleček

Izhodišča: Dvostopenjska rekonstrukcija dojke s tkivnim razširjevalcem po obsevanju ima visok odstotek zapletov. Zaradi obsevanja otrdela povrhnje ležeča mehka tkiva in oslABLJENA konsistenca reber povzročita, da se ima tkivni razširjevalec tendenco pomikati tudi v posteriorni smeri, kar poveča možnosti za deformiranje prsnega koša.

Prikaz primera: Predstavljamo primer 40-letne bolnice, pri kateri je bila opravljena sekundarna rekonstrukcija prej obsevane desne dojke in primarna rekonstrukcija leve dojke, oboje s tehniko dvostopenjske rekonstrukcije s tkivnim razširjevalcem. Prva operacija in pooperativen potek je bil brez posebnosti. Po številnih polnjenjih tkivnih razširjevalcev je bil končni volumen desno 400 ml in levo 260 ml. Med drugo operacijo je kirurg opazil izrazito konkavno deformacijo prsnega koša s 5 cm dolgo depresijo četrtega in petega desnega rebra, vključno z znaki za star zlom četrtega rebra. Zaradi nastale volumske spremembe je bolnica dobila večji trajni vsadek z večjo projekcijo, s katero je bila dosežena idealna oblika in simetrija obeh dojk.

Zaključki: Bolnice po radioterapiji in dvostopenjski rekonstrukciji dojke s tkivnim razširjevalcem so bolj podvržene različnim spremembam prsnega koša kot bolnice, ki niso bile obsevane. Če med operacijo opazimo depresijo reber s prisotnim zlomom ali brez njega, je potrebno razmisliti o vstavitvi večjega trajnega vsadka in deformacijo radiološko opredeliti. V prihodnosti bi lahko razvoj novih tkivnih razširjevalcev s tršo bazo zmanjšal tovrstne zaplete.

Background

According to the annual report of the American Society of Plastic Surgeons from 2013, the two-stage tissue expander reconstruction is the most commonly performed breast reconstruction technique with the most predictable final results.¹ Nowadays, an increasing number of women with breast cancer require postmastectomy radiotherapy (PMRT).² Large randomized trials have already shown benefits of PMRT, with lower lo-

co-regional recurrence rates, prolongation of disease-free period and an improvement of the overall survival.

The most recent studies show that in the setting of a two-stage tissue expander breast reconstruction, women undergoing PMRT have statistically higher complication rates in comparison to women without PMRT.^{2,3} Most common complications include severe capsular contraction (Baker grade III or

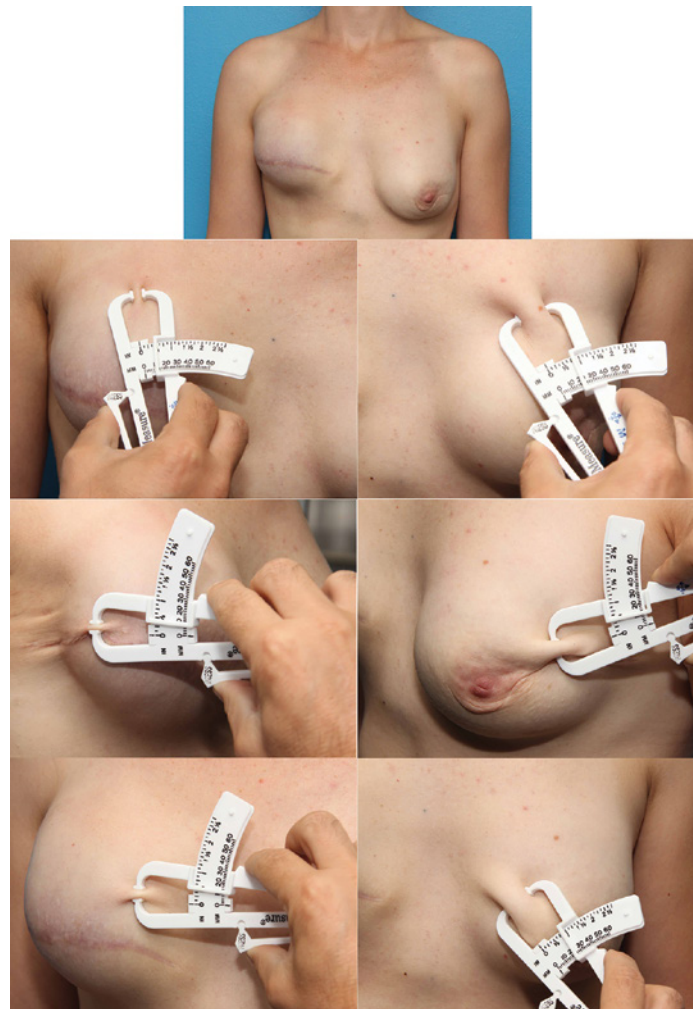


Figure 1: Patient before 2nd operation, where both expanders have reached final end volume. Left sided pictures are showing thin skin envelope, while right-sided picture are showing thick skin envelope, measured on different locations with a skin-fold calliper.

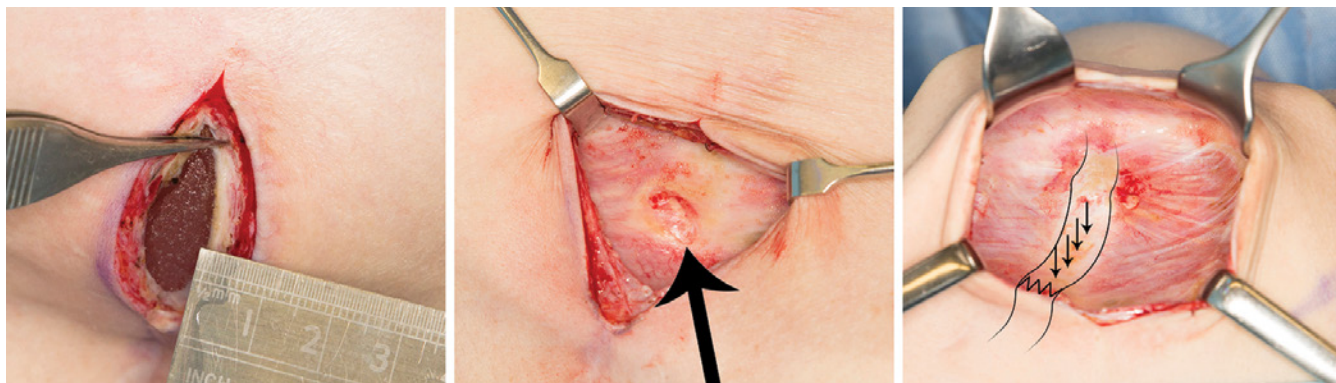


Figure 2: Intra-operative pictures. Formation of thick capsule around the tissue expander (left picture); thick black arrow shows fracture of the 4th right rib (middle picture); thin black arrows showing a 5 cm rib depression (right picture).

IV), rippling, tissue expander exposure, inadequate soft-tissue envelope coverage, implant malposition, skin necrosis, delayed wound healing, wound dehiscence and infection. However, it is still a reasonable surgical option.²

Other, less known complications during tissue expansion include various forms of rib cage deformities, such as flattening, concavity or even fractures.⁴⁻⁹ Most deformities do not cause any problems but some cause pain and/or discomfort and can even severely compromise the final aesthetic result. Whenever intra-operative rib cage depression with or without fracture is noticed, surgeon should consider altering reconstructive plans by inserting an implant with greater volume and bigger projection than previously intended. With this case report, we would like to point out the significance of rib cage deformity in previously irradiated patients undergoing two-stage tissue expander breast reconstruction and present appropriate measurements that need to be taken in order to achieve the best aesthetic result.

Case presentation

In 2012, a 40-year-old patient developed cancer (DCIS; Her 2 positive) in her right breast. A surgical oncologist

performed total mastectomy with sentinel node biopsy (SNB). According to histological examination of breast tissue, adjuvant radiotherapy and chemotherapy were needed.

Two years after completed adjuvant treatment, the patient decided to have a prophylactic skin-sparing (SS) mastectomy of her right breast. Oncological-reconstructive multidisciplinary team (MDT) recommended her a secondary reconstruction of her right breast and a primary reconstruction of her left breast, both with a two-stage tissue expander technique.

In December 2013, both breasts were operated on in a single surgical procedure. First, a breast surgeon performed SS mastectomy on her left breast with SNB, and later on, a plastic surgeon inserted a tissue expander under the pectoral muscle, on the basis of previous measurements. A tissue expander was also inserted under the right pectoral muscle as a part of the secondary reconstruction. Both expanders were intra-operatively filled with 140 ml of saline solution. Operation was performed under general anaesthesia and lasted 2 hours and 30 minutes. Postoperative recovery was uneventful and the patient was discharged 4 days later.

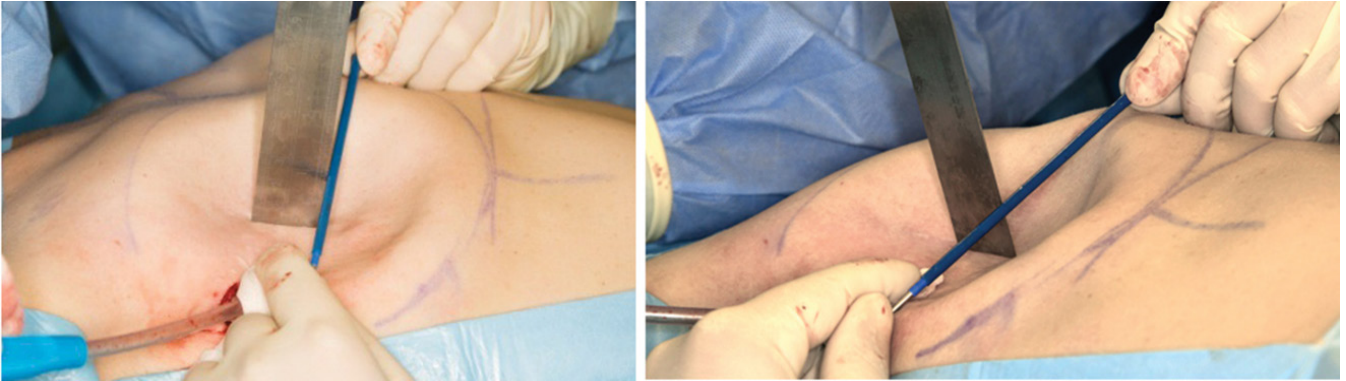


Figure 3: Pictures show the extent of rib cage depression (2.5 cm measured with a meter).

One month later, she started receiving her regular expander fillings at the outpatient clinic of plastic surgery. During three-week intervals, expanders were filled with 20–100 ml of saline solution, until the final volume of the right expander reached 400 ml, and that of the left one 260 ml. The right expander needed to be over-expanded in order to gain extra skin on the lower pole, because of expected retraction due to previous radiotherapy. The difference in soft tissue coverage can be seen in Figure 1.

Three months after the final expansion, a second operation was performed in which both expanders were replaced with permanent anatomically shaped silicone implants according to preoperative measurements (left – *Mentor CPG™ 332*, 295 cm³; right – *Mentor™ 323*, 390 cm³). During the operation, surgeon noticed a thick capsular contraction, which was also clinically evident before the operation (Figure 2). When the expander was removed, he noticed a substantial abnormal concave deformity of the 4th and 5th right ribs, with signs of an old 4th rib fracture. (Figure 3). The surgeon had to insert implants with greater volume than previously expected. He estimated that the implant should be 100 cm³ bigger in order to adequately

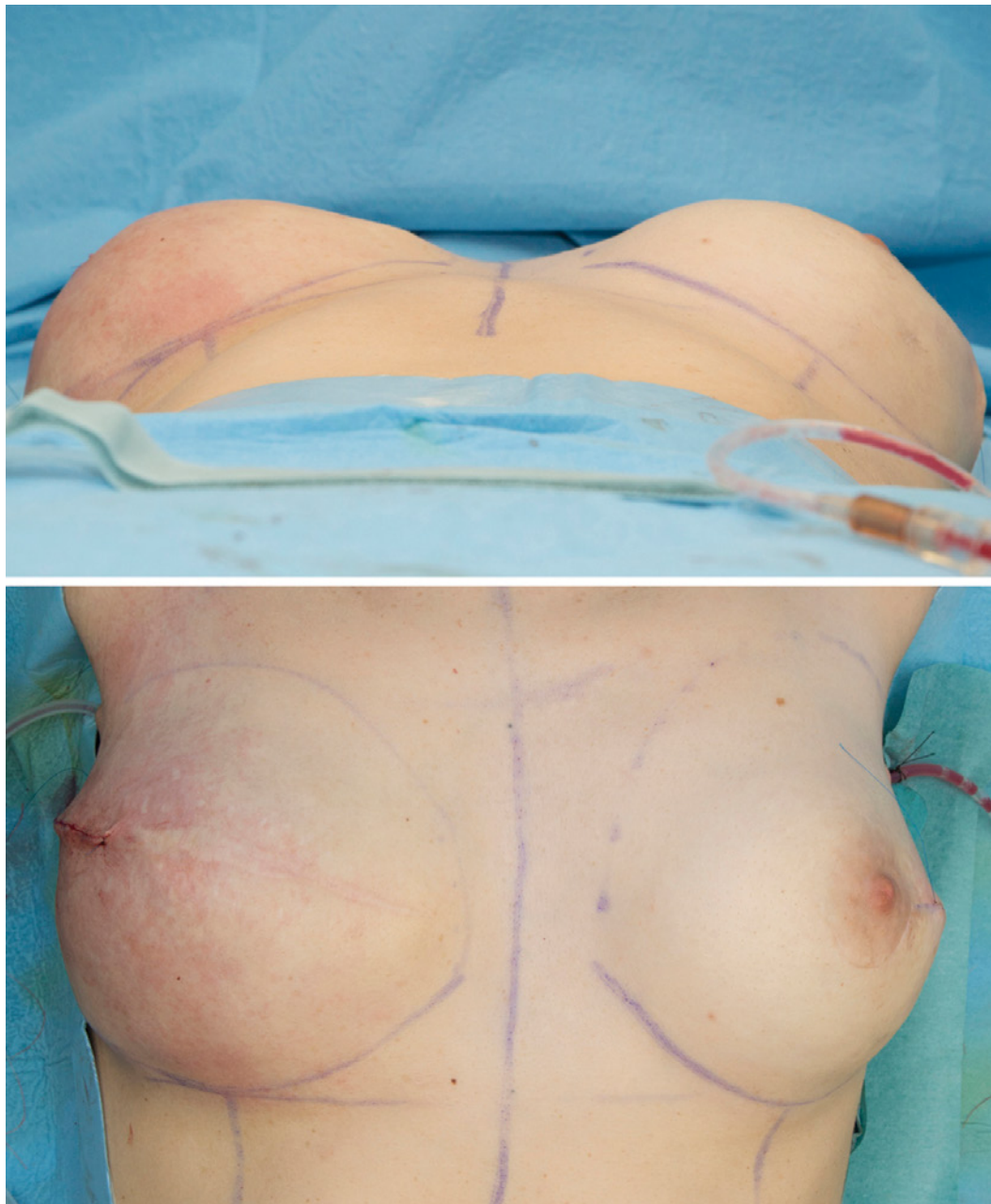
fill the depression volume and at the same time achieve good aesthetic result (Figures 4 and 5). The operation was performed under general anaesthesia and lasted 2 hours.

A few days after the operation, a CT scan was performed to evaluate intra-operative findings (Figures 6 and 7). The 4th right rib had a 5 cm long depression in the anterior costal part, with signs of an old fracture in the medial axillary line. The fracture had already shown signs of sclerosis with early callus formation – typical for an older fracture. There was also a slight depression of the 5th right rib in the anterior costal part with minimal sclerosis. At the level of the 4th and 5th right ribs, the posterior surface of the implant was protruded. Detailed analysis of the thorax showed no evidence of local cancer recurrence. The patient's hospital recovery went without any complications; she was discharged 8 days later. Figure 8 shows patient's progress and aesthetic results through different reconstructive stages.

Discussion

Although previous breast radiotherapy is associated with a high risk of complications in the setting of a two-stage tissue expander breast reconstruction, it

Figure 4: Cranial (upper picture) and superior (lower picture) views immediately after the placement of permanent anatomically shaped silicone implants.

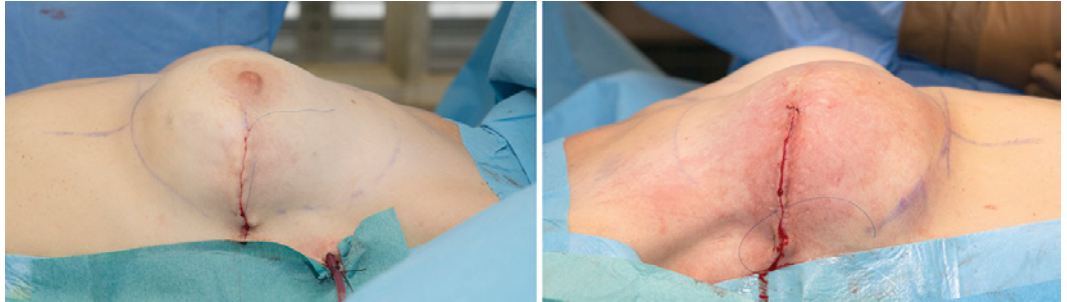


still remains a widely used breast reconstruction technique. Some authors argue that in patients with a history of irradiation, tissue expansion should be avoided, and alternative methods (e.g. autologous reconstruction) used instead.⁵

Rib cage deformity after tissue expansion is not so commonly described complication. Harith et al. found that women who had radiotherapy and tissue expander breast reconstruction developed rib cage deformities in almost three quarters (70.2%), whereas in control group

without radiotherapy, the overall rate of rib cage deformity was found to be only one third (32.6%). Radiotherapy group had more severe forms of deformities, including concave deformities and rib fractures, whereas control group had only signs of simple rib cage flattening.⁴ The changes in rib cage are usually progressing slowly and are not associated with pain that usually follows after tissue expansion. Importantly enough, every patient with a rib cage deformity also had severe capsular contraction covering the

Figure 5: lateral left (left picture) and lateral right (right picture) view immediately after the placement of permanent anatomically shaped silicone implants.



tissue expander, which can influence the size of permanent implant that is going to be inserted in the 2nd stage.

The exact mechanism of rib cage deformity is currently unknown, however, there are some possible explanations. Despite advances in radiotherapy, it still has some adverse effects on the irradiated tissues, especially on the soft tissues that are adjacent to the lateral edge of the expander. Acute effects on the skin and soft tissue are transitional and include radiation dermatitis (erythema, desquamation, vesicle formation, ulcerations and necrosis). Late effects are long-lasting and include anatomic and physiologic changes of the skin: atrophy of the dermis, destruction of elastic fibres, formation of thick fibrous tissue and skin retraction, which all lead to tightening of the stiff overlying soft tissue coverage.¹⁰ High incidence of severe capsule contraction (Baker III or IV) can further compromise elasticity of the overlying soft tissue. However, capsular contraction forms all around the implant, including on the posterior side adjacent to the rib cage, which could minimise the effect of posterior expander protrusion.

After breast cancer radiotherapy, rib fractures are an uncommon finding and occur in 0.3–2.2 % of patients.¹¹ Older studies found that significantly higher rates of spontaneous fractures occurred when greater radiation doses were administered to breast cancer patients.¹² The effect of radiation on the bone includes osteoradionecrosis and radiation-induced vascular changes, which severely im-

pair osteoblastic activity and bone matrix formation. The reduction of mineral bone density can lead to osteopenia or even osteoporosis, which substantially increases bone fragility.¹³ Additional chemo- and hormonal therapy can also influence bone metabolic activity and further increases fragility.⁴ Pre-expansion DEXA scan could give us more information about the extent of radiation-induced osteoporosis, but its applicability still needs to be tested.⁴

The expansion protocol could also be another important factor that can make rib cage more prone to deformation.⁴ Some authors think that with shorter time intervals between expansions, the overlying fibrotic tissue with thickened capsule cannot adequately stretch and adjust. The tendency to expand could therefore be directed more towards the ribs.⁴ Because the irradiated side can only tolerate smaller filling volumes, it is advisable to have expansions every three weeks, with smaller filling volumes.⁷ But on the other hand, formation of fibrotic tissue is a slow process, which becomes more prominent after a few months. We therefore advise that the expansion should be performed relatively quickly, before the rigid fibrotic tissue is formed.

Whenever two-stage breast reconstruction in irradiated patients is performed, surgeons should always have a prior consultation with the patient about all the possible complications, including rib fracture.⁴⁻⁷ However, rib fracture can also occur in non-irradiated breasts which depends on the expansion veloci-

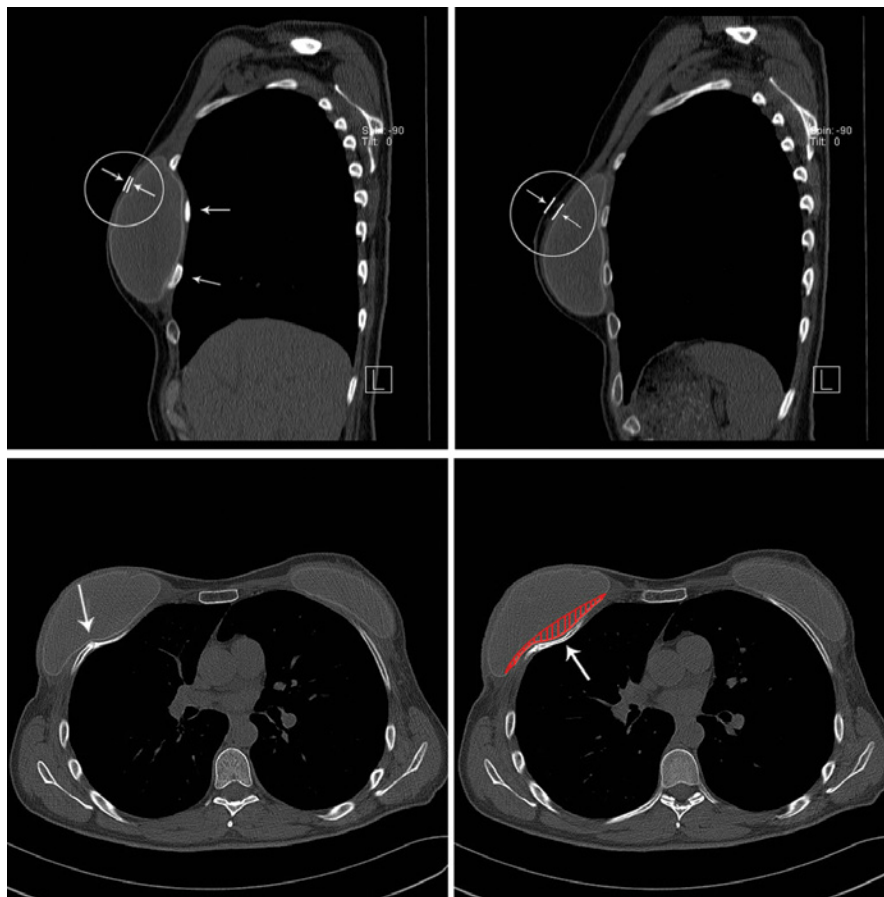


Figure 6: CT scan of the thorax after the positioning of permanent anatomically shaped silicone implants (sagittal section – upper, transverse section–lower). The left upper picture shows the position of the right implant, whereas the right upper picture shows the position of the left implant. Notice that the right implant is protruding posteriorly and that the 4th and 5th ribs are also displaced posteriorly, away from their normal position (smaller arrows). Arrows in both circles also indicate different thickness of the overlying soft tissue envelope. Lower pictures indicate fracture of the 4th rib on the right side (left bigger arrow) and a posterior protrusion (right bigger arrow) of the implant in two adjacent transverse sections. The left 4th rib shows no signs of fracture or protrusion. The area covered with red stripes indicates the overall volume of implant depression. Implant dimensions: Left–CPG™ 322 (295 cm³); width 11.5 cm; height 10.8 cm; projection 4.9 cm. Right–CPG™ 323 (390 cm³); width 12.0 cm; height 11.3 cm, projection 6.0 cm

ty, end volume of single expansion and coincidental sudden movements, as previously described.⁹ At every expander filling the surgeon should ask the patient for any history of sudden sharp pain (after caught, sneeze, sudden moves). Prolonged pain after expansion (more than 24 hours) should also raise the suspicion for possible rib fracture. A surgeon should also pay attention to the lack of projection after expansion and asymmetry in the setting of bilateral expansion.⁴ CT scan of the thorax is at the moment not

used routinely prior to expander implant exchange in previously irradiated breasts. Surgeons should consider such investigations individually, according to the patient's history and intra-operative findings. Radiological imaging can objectively evaluate the extent of the deformity and can also exclude very rare pathological metastatic fractures.

If intra-operative findings suggest a substantial rib cage depression, the surgeon must consider placing a bigger implant with greater projection than

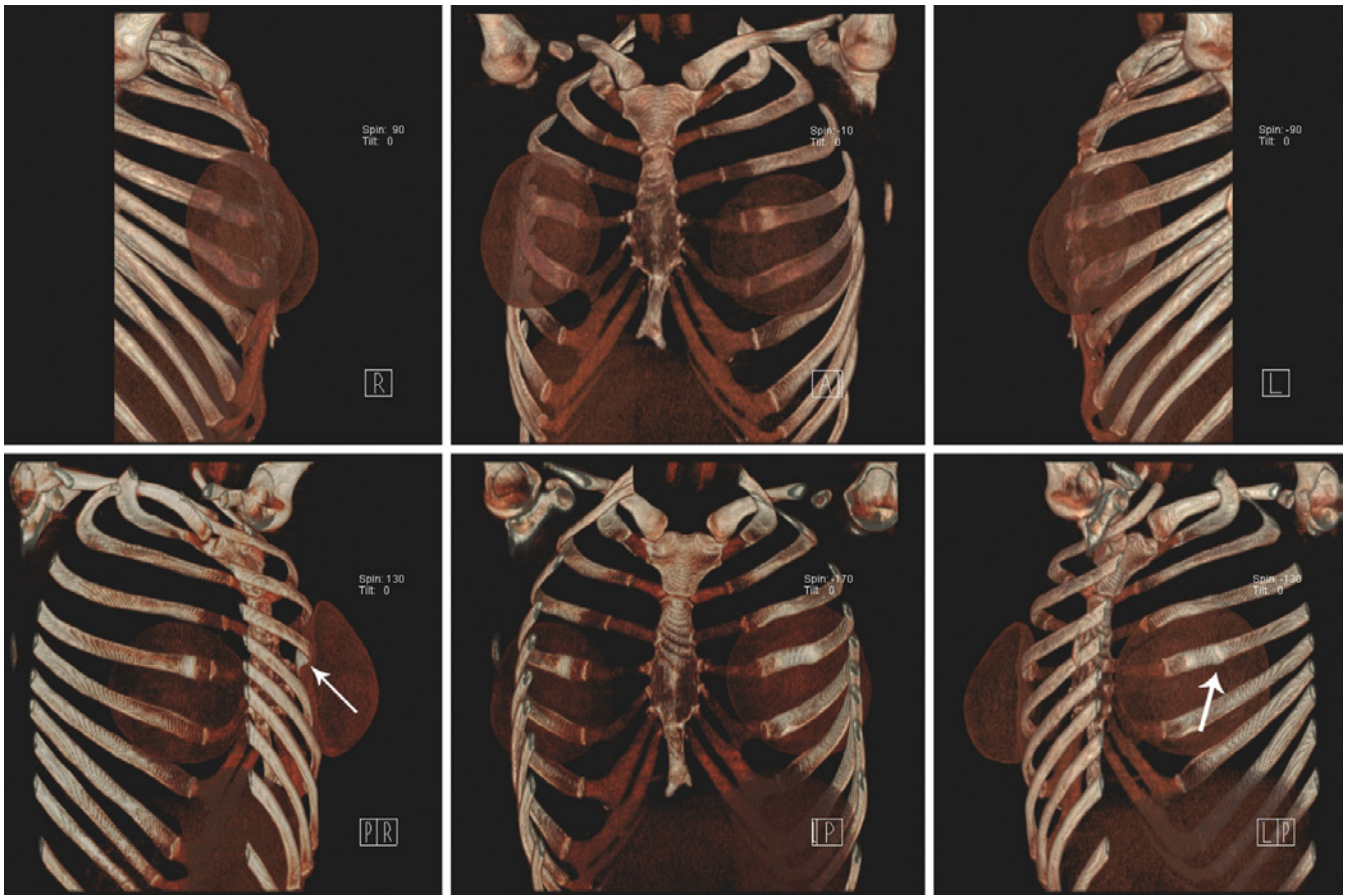


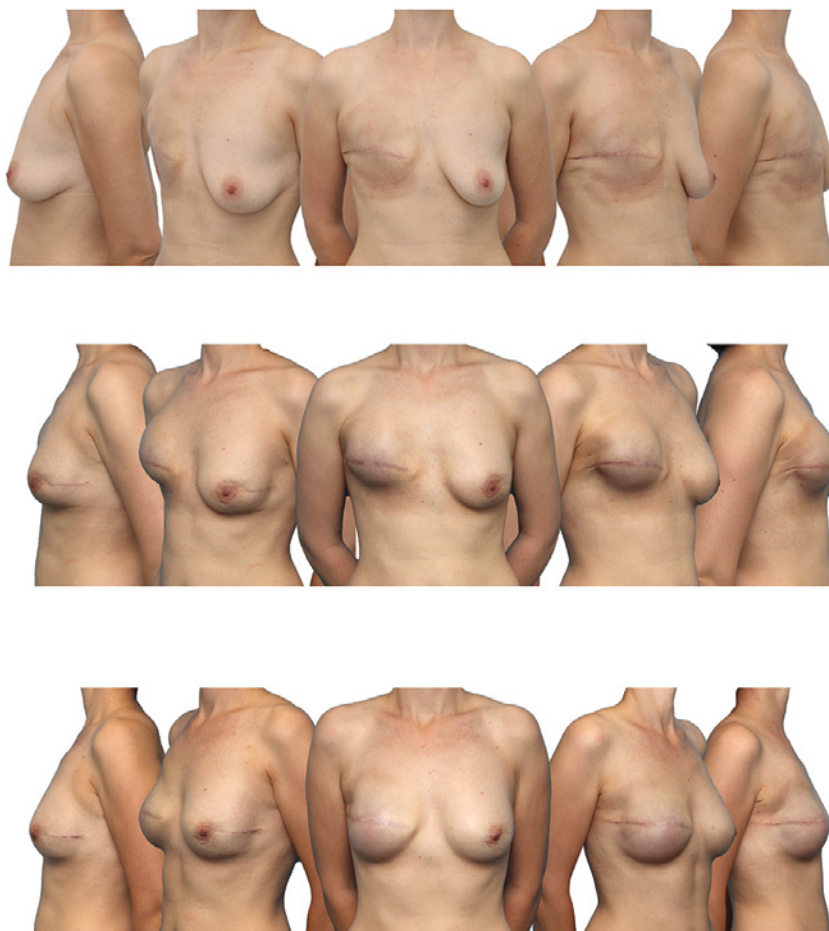
Figure 7: 3D surface shaded display from thoracic CT data after the positioning of permanent anatomically shaped silicone implants. The upper sequence shows the rib cage in anterior-posterior direction, the lower sequence shows the rib cage in posterior-anterior direction. In the lower right picture note a fracture of the 4th right rib (thick arrow). On the lower left picture note that the 4th right rib is protruding posteriorly (thin arrow).

previously expected. Currently, there are no recommendations on how much volume the surgeon should add in order to compensate for the volume of rib cage depression; experience here plays a vital role. In our case, a fracture of 4th rib with a 5 cm long depression and a slight depression of the 5th rib required approximately 100 cm³ more volume.

In order to minimise rib cage deformities in patients undergoing tissue expansion of a previously irradiated breast, we suggest that a new, modified tissue expander with a harder and more rigid base should be developed. In this proposed model, changed physical properties of a tissue expander base would

act protectively against softer underlying rib cage. During regular expander fillings, expander would have the tendency to protrude more anteriorly in the direction of its softer envelope rather than posteriorly in the direction of its more rigid base. However, this modified expander could not prevent events such as rib fractures, which can occur due to other independent factors (sudden movements, ...). The new expander base should still have some elastic properties so that the incision line would not be significantly longer. This is only a hypothesis; a pilot study needs to be performed in order to confirm the assumption.

Figure 8: Upper sequence is showing patient after right mastectomy with signs of radiation dermatitis after radiotherapy. Middle sequence is showing the patient before the exchange of both expanders for permanent implants after secondary two-stage expander-implant reconstruction in right breast and primary two-stage expander-implant reconstruction in left breast. Lower sequence is showing patient 1 month after the final operation.



Conclusion

Two-stage tissue expander breast reconstruction in the setting of radiotherapy has a high complication rate, including rib fractures. Rigid overlying soft tissue structures and softer integrity of underlying ribs most likely contribute to chest-wall deformities. If a

substantial depression with or without rib fracture is found intra-operatively, a larger implant with greater projection should be placed instead, followed by subsequent radiological evaluation. The development of new tissue expanders with a more rigid base could significantly reduce the incidence of such complications.

References

1. 2013 Plastic Surgery Statistic Report [American society of plastic surgery web site]. Dostopno 9. 12. 2014 s spletne strani <http://www.plasticsurgery.org/Documents/news-resources/statistics/2013-statistics/plastic-surgery-statistics-full-report-2013.pdf>.
2. Ho AL, Bovill ES, Macadam SA, Tyldesley S, Giang J, Lennox PA. Postmastectomy radiation therapy after immediate two-stage tissue expander/implant breast reconstruction: a University of British Columbia perspective. *Plast Reconstr Surg* 2014; 134: 1–10.
3. Kronowitz SJ. Current status of implant-based breast reconstruction in patients receiving post-mastectomy radiation therapy. *Plast Reconstr Surg* 2012; 130: 513–24.
4. Alani H, Shantour S. Breast reconstruction by tissue expander after radiotherapy: When the skin does not expand, the rib cage is at risk. *Eur J Plast Surg* 2014; 37: 333–8.

5. de Wildt R, Tuinder S, van der Hulst RWJ. Substantial chest-wall deformity following tissue expansion after radiotherapy. *Eur J Plast Surg* 2009; 32: 337–40.
6. Tseng J, Huang AH, Wong MS, Whetzel TP, Stevenson TR. Rib fractures: a complication of radiation therapy and tissue expansion for breast reconstruction. *Plast Reconstr Surg* 2010; 125: 65–6.
7. Tirone L, La Rusca I, Ciccarelli F. Rib fracture as a complication of tissue expansion in breast reconstruction. *Plast Reconstr Surg* 2010; 126: 2290–1.
8. Huang AH, Wong MS, Whetzel TP, Stevenson TR. Rib fractures: a complication of radiation therapy and tissue expansion for breast reconstruction. *Breast Cancer Res Treat* 2007; 106: 1 Suppl: 238.
9. Ahcan U, Zivec K. Rib fracture after breast reconstruction with tissue expander. *Zdrav Vest* 2009; 78: 413–6.
10. Wong S, Kaur A, Back M, Lee KM, Baggarley S, Lu JJ. An ultrasonographic evaluation of skin thickness in breast cancer patients after postmastectomy radiation therapy. *Radiat Oncol* 2011; 6: 9.
11. Hirbe A, Morgan EA, Uluçkan Ö, Weilbaeher K. Skeletal Complications of Breast Cancer Therapies. *Clin Cancer Res* 2006; 12: 20 Suppl: 6309–63.
12. Overgaard M. Spontaneous radiation-induced rib fractures in breast cancer patients treated with postmastectomy irradiation. A clinical radiobiological analysis of the influence of fraction size and dose-response relationships on late bone damage. *Acta Oncol* 1988; 27: 117–22.
13. Monticciolo DL, Sinclair ST, Hajdik RL. Rib Fracture as a Complication of Accelerated Partial Breast Irradiation Diagnosed on MRI. *Breast J* 2010; 16: 424–7.