

Role of the ribs in the onset and progression of idiopathic scoliosis

Andrej Gogala

*Slovenian Museum
of Natural History,
Ljubljana*

Correspondence:

Andrej Gogala,
e: agogala@pms-lj.si

Key words:

spinal deformities;
idiopathic scoliosis;
scoliosis pathogenesis;
thorax; bone remodeling

Cite as:

Zdrav Vestn. 2017;
86:404–13.

Received: 12. 1. 2017

Accepted: 20. 7. 2017

Abstract

The pathogenesis of idiopathic scoliosis is still a matter of debate as its common cause has not been found. But some basic principles of its onset and progression do exist. The curvature of the spine is always accompanied by rotation of the vertebrae and rib cage. If we want to explain the principles governing scoliosis onset and progression, we should answer some questions. First, why is side curvature of the spine always accompanied by rotation of the rib cage and vertebrae and vertebral rotation is maximal at the curve apex? Second, is structural scoliosis fixed by primary bone growth in growth plates of the vertebrae or by bone remodeling by which bones adapt to external loads? Third, why most of the curvatures are right thoracic? And fourth, what drives the progression of scoliosis? In the theory presented here, attention is given to the role of the ribs. Symmetrical rib cage fixes vertebrae in the midline of the body and prevents rotation of the vertebrae with dual articulating surfaces on each side of the vertebrae. The ribs are connected with intercostal muscles and cannot spread apart on the convex side when the spine bends. Curvature of the spine in the thoracic region is not possible without rotation of the vertebrae and deformation of the ribs. The ribs at the apex of the curve are pulled inwards towards the vertebrae because they are shifted further from the midline than other ribs. With rotation of the vertebrae at the apex of the curve, which are compressed between the ribs, the thoracic circumference diminishes and the tension in the wall is alleviated. The deformation becomes irreversible if new bone growth or resorption and remodeling change shape of the ribs and vertebrae or if ligaments are not firm enough. Bone remodeling is probably more important than primary bone growth in fixing the structural scoliosis. When the rib cage and vertebrae become structurally rotated, vertebrae lose balanced support from the ribs from both sides. Shear forces from the ribs turn vertebrae further and push vertebral bodies toward the convexity. Thus, continuous progression of scoliosis starts.

Cite as: Zdrav Vestn. 2017; 86:404–13.

1. Introduction

Scoliosis, the side curvature of the spine, was known from the time of Hippocrates (1). Today, it is defined as a three-dimensional torsional deformity of the spine and trunk (2). Many different hypotheses were postulated on its etiology, but no common cause had been found (3). Congenital scoliosis is caused by a defect in spine structure present at birth. Neuromuscular scoliosis develops because of neuronal or muscular disorders in which nerves and muscles are unable to maintain appropriate balance of the spine and trunk. But in most cases of scoliosis, in 80–90 %, the cause is unknown (4). Idiopathic scoliosis de-

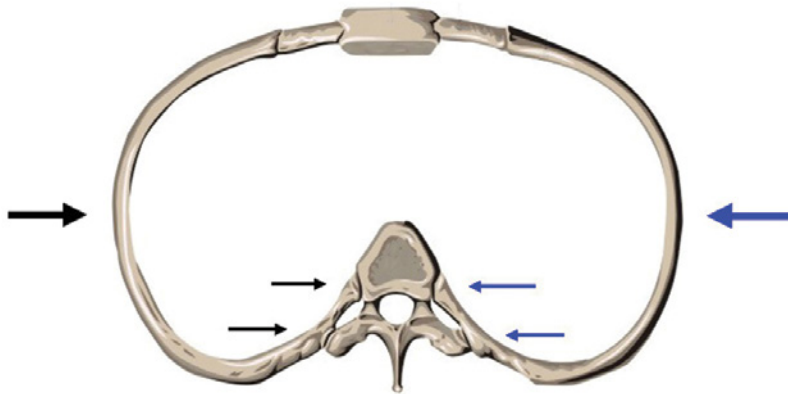


Figure 1: Ribs of a symmetric chest stabilize the vertebrae and straighten the spine. They fix the vertebrae in the midline of the body and prevent rotation of the vertebrae with dual articulating surfaces on each side of the vertebrae.

velops most often during adolescence and is much more common in girls than in boys. Adolescent idiopathic scoliosis affects 1–4 % of adolescents (5). Clinicians treating patients with adolescent idiopathic scoliosis are often impressed with the absolutely normal development of the patient, both intellectually and physically, up to the moment that the spine starts to grow crooked (6). If we want to explain the principles governing scoliosis initiation and progression, we should answer some questions: (1) Why is side curvature of the spine always accompanied by rotation of the rib cage and vertebrae and vertebral rotation is maximal at the curve apex? (2) Is structural scoliosis fixed by primary bone growth in growth plates of the vertebrae or by bone remodeling by which bones adapt to external loads? (3) Why most of the curvatures are right thoracic? and (4) What drives the progression of scoliosis? Some alternative views to the prevailing explanations are discussed below. Attention is given particularly to the role of the ribs.

2. Curvature and rotation

Human spine is a vertical column of 24 articulating segments, seven cervical, twelve thoracic and five lumbar vertebrae separated by intervertebral discs. Such a structure would be very unstable and prone to collapse without additional support. Backwardly inclined vertebrae in the middle and lower thoracic regions of the spine are especially rotationally unstable due to dorsal shear forces (7,8). Ligaments and muscles provide some support but are not able to prevent rotation or buckling of the vertebral column. The role of the rib cage is essential for the stability of the human spine. Each of the thoracic vertebrae are supported by a pair of ribs, connected in front by the sternum and costal cartilage. Ribs articulate with vertebrae at two points, one on the vertebral body and the other on the transverse process. Symmetrical rib cage fixes vertebrae in the midline of the body and prevents rotation of the vertebrae with dual articulating surfaces on each side of the vertebrae (Fig. 1).

When somebody leans or curves to the side, the spinal column bends. The gaps between the ribs on the convex side should become larger in this case. However, this is possible only to a very limited degree and is even more limited during rapid growth spurts when the distances between ribs become larger in a short time because of vertebral growth. Ribs are connected by intercostal muscles and cannot spread apart. In a scoliotic skeleton, ribs are also aligned parallel to each other on the convex side. Otherwise, breathing would not be possible. When the spine is curved to the side, a tension builds up in the thoracic wall. It can be released only with rota-

tion and deformation of the rib cage which is possible due to flexibility of the ribs and especially the costal cartilage. Ribs at the apex of the curve are pulled inwards towards the vertebrae because they are shifted further from the midline than other ribs (Fig. 2). With rotation of the vertebrae at the apex of the curve, which are compressed between the ribs, the thoracic circumference diminishes and the tension in the wall is alleviated. Axial rotation of vertebrae is maximal at the curve apex in scoliosis (9), but the mechanism responsible for that has not been explained. Vertebrae could rotate in both directions, but slight rotation to the right already exists in the thoracic vertebrae of adolescents (10) and paravertebral muscles at the back prevent rotation to the opposite side together with ligaments at the processes. Back muscles are known to be active and stronger on the convex side of the scoliotic thorax (3). As a result, the vertebrae and rib cage rotate to the convex side. This is a kind of sprain, a sprain of the chest. It is reversible as long as the ribs and ligaments are flexible enough to regain their original form upon straightening of body posture. It is called functional or nonstructural scoliosis. But when bone structure is remodeled after bone resorption stimulated by frequent deformations, the rotated ribs and vertebrae become fixed in the new position, and structural scoliosis develops. If joint ligaments are not firm enough, the deformation of the rib cage becomes easier irreversible. Scoliosis develops in patients with congenital laxity of connective tissue (11,12), and in children with idiopathic scoliosis joint hypermobility occurs more frequently than in healthy controls (13).

Rotation of the vertebrae in idiopathic scoliosis is usually explained as a re-

sult of hypokyphotic or lordotic thoracic spine because of anterior spinal overgrowth. According to this theory, the relatively shorter posterior column of the spine acts as a tether which hinders the lengthening of the anterior column during the period of rapid growth, forcing the spine to bend and rotate (14). However, the growth disturbance is confined to the area around the apex of the curves, the junctional zones are straight (15). This means that the difference in length is not the cause but a consequence of bending. Anterior overgrowth occurs in neuromuscular scoliosis with a known origin as well. The fact that the intervertebral discs contribute more to increased anterior length than the vertebral bodies suggests an adaptation to altered loading, rather than a primary growth disturbance (16). Be the cause of bending and twisting this or another, biomechanics of the chest will be the same. Bending of the thoracic spine is not possible without rotation, and the coupling of both phenomena is inevitable.

In the lumbar part of the spine ribs are absent. Torsion of the lumbar vertebrae in the lumbar curve of the spine is caused by lumbar muscles that attach to the transverse processes of the lumbar vertebrae, lowest ribs and the pelvis (17).

3. Bone growth and remodeling

Most spinal deformities begin as a nonstructural scoliosis (18). With time, the deformations are fixed by structural changes. Vertebrae can become wedge-shaped and this is usually regarded as the crucial step in the development of structural scoliosis. As scoliosis develops most frequently in adolescents during rapid growth spurts, the role of primary bone growth is regarded as re-

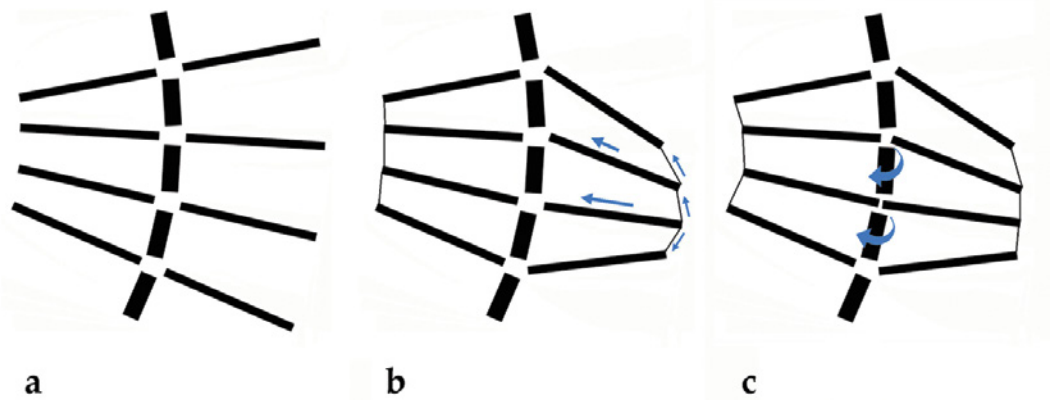


Figure 2: A schematic representation of the ribs and vertebrae. When the spine bends, the ribs would spread apart on the convex side if they were free (a). In reality, they are connected by the intercostal muscles (b). Forces (arrows) pull the ribs at the apex of the curve towards the vertebrae which rotate to alleviate the tension. With rotation of the vertebrae at the apex of the curve, the thoracic circumference diminishes (c).

sponsible for the abnormalities. While vertebrae of an adult change shape only with bone remodeling, in a child they grow in length. Growth takes place with ossification of cartilage in growth plates under the articulating surfaces. In the twisted spine, unevenly loaded cartilage is compressed on the concave side and stretched on the convex side. According to the theory, the bone grows faster on the convex side of the vertebral growth plates producing wedge shaped vertebrae (19). Observational study of the vertebral body growth plates in scoliosis involving high-resolution coronal plane magnetic resonance imaging and histological examination, however, did not prove this theory (20). In 13 scoliotic spines, convex and concave side growth plate deficiencies were observed most frequently at or near the apex of the curve. The degree of vertebral body wedging was independent of the presence of vertebral body growth plate deficiency. The finding that vertebral body growth plate deficiencies occurred both on the convex and concave sides of the spine, closest to the apical vertebra of the scoliosis curve, implied that they

are less likely to be the result of adaptive changes to the physical forces involved in the scoliotic deformity.

Wedge-shaped vertebrae are not always present in scoliosis; in many cases cartilaginous intervertebral discs are more prone to transformation. Disc wedging dominates over vertebral wedging in curves in the lumbar and thoracolumbar regions (21). The curvature usually also progresses slowly in adulthood. Linear rate of progression at about one Cobb degree per year had been demonstrated in progressive adult scoliosis (22). Scoliosis can also appear anew in adulthood, when only bone remodeling can be blamed for it.

In scoliosis, the vertebrae are not the only bones that change its form. Ribs are even more markedly transformed. Ribs on the convex side are pushed posteriorly and the thoracic cage is narrowed by more strongly curved ribs which form a rib hump. Ribs on the concave side are pushed laterally and anteriorly. There are also other changes of the vertebrae besides wedging. Vertebral body is distorted toward the convex side, spinous process deviated to the concave side,

vertebral canal is narrower on the convex side and lamina thinner. All these changes can be at least partially attributed to bone remodeling which is a very active process during growth. Without it, the growing bones would be too heavy. Bones are wider at the ends where growth plates are and hollow in the center. Osteoclasts must resorb the excess bone (23). Besides that, microcracks in the bone induced by stress stimulate Haversian remodeling that replaces fatigue bone with new bone matrix (24). Deformations of the ribs during rotations of the rib cage may cause microcracks to appear and induce targeted remodeling of the ribs. Bone remodeling slows down with adulthood, but never completely ceases.

The transformation of vertebrae and ribs in the process of bone remodeling is regulated by several hormones. One of them is melatonin, secreted by the pineal gland at night. In chickens and rats with destroyed pineal gland scoliosis developed, but the administration of melatonin prevented that (25). It was suggested that a lack of melatonin could also be the cause of idiopathic scoliosis in humans, but such a shortage was usually not detected in scoliotic patients (26). Melatonin receptors can be impaired (27). Melatonin suppresses bone remodeling by inhibition of bone resorption (28). When there is a shortage of melatonin, bone remodeling accelerates.

Leptin, secreted by adipose tissue, is also among the hormones suspected to have a role in the development of scoliosis. In bipedal mice leptin increased the incidence of scoliosis (29). In girls with adolescent scoliosis, lower leptin levels were observed in the blood, but an increased effect of leptin in the brain with higher soluble leptin receptor levels. Leptin inhibits the production and release of the neurotransmitter serotonin

in the brain (30). The consequences of reduced secretion of serotonin are appetite loss, reduced self-confidence or a feeling of security and increased activity of the sympathetic nervous system. This prevents the accumulation of bone mass, namely inhibits the second part of bone remodeling, the formation of new bone tissue, and favours bone resorption. The activity of the sympathetic nervous system produces a lightweight skeleton with long limbs, such as prevalent in girls with adolescent scoliosis.

Ishida *et al.* (31) found an increased amount of bone resorption marker in the majority of patients with adolescent idiopathic scoliosis, while the bone formation marker was at a normal level. Thus, in them bones degrade faster than regenerate. This decreases the strength of the bone and can lead to osteoporosis.

Decreased bone mineral density has been reported also in children after transplantation. A number of factors may compromise bone quality in these subjects, but immunosuppression with glucocorticoids is among the most important as these hormones stimulate bone resorption. In a study of pediatric transplant patients who were on a triple drug immunosuppressive medication one fifth of all transplant children developed scoliosis. Of those patients reaching skeletal maturity, one third showed scoliosis. The risk of scoliosis was three-fold as compared with control population. However, the risk of brace or operative treatment (progressive scoliosis) was up to seventeen-fold higher (32).

4. Curve direction

Goldberg & Dowling found a statistically significant correlation between scoliosis configuration and handedness in 254 girls with idiopathic scoliosis (33). The curve pattern matched handedness

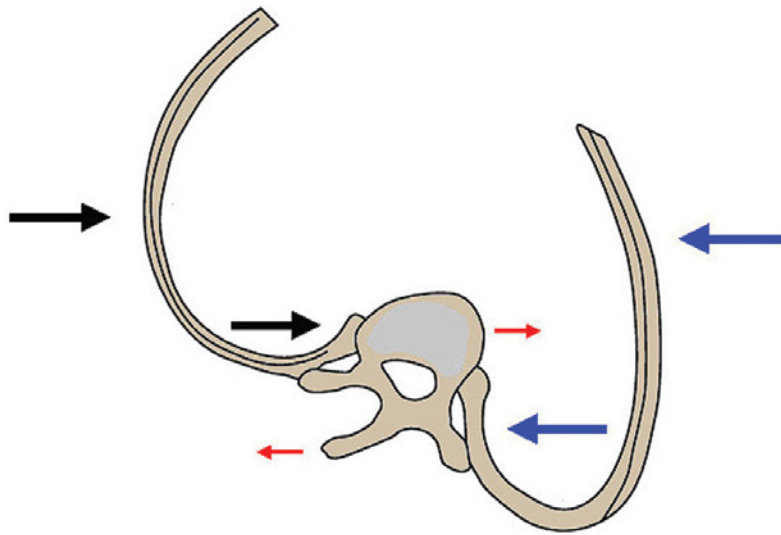


Figure 3: In a rotated chest, the forces transmitted by the ribs turn the vertebrae and bend the spine sideways. The ribs on one side of the vertebrae are not opposed by equal support from the ribs on the contralateral side, so the ribs on the concave side push vertebral bodies toward convexity, thus bending the spine.

in 82 percent. Of 228 right-handed children, 197 had a right convex curve pattern; of 26 left-handed children, 12 had a left convex pattern. In an extremely rare case of monozygotic twin boys with Duchenne's muscular dystrophy and opposing hand dominance major spine curvature with opposite convexities developed (34). However, due to preexistent vertebral rotation to the right found in healthy spine (10), curves directed to the right have a greater potential for development.

Scoliosis without an obvious cause occurs only in humans. The same is true also of handedness: lateralization has not evolved to a similar degree in any other vertebrate. The influence of handedness on the curvature may be mediated through posture. When a child sits and writes with her right hand, she often bends to the left. Bones are loaded asymmetrically and scoliosis develops in children with rapid bone resorption and remodeling. Adolescent idiopathic scoliosis develops when children go to school

and start to write or do other activities in which the dominant hand is used. They sit for prolonged periods, often in unbalanced sitting position to which they become accustomed.

5. Progression

Progression of idiopathic scoliosis is usually explained as uneven growth of vertebrae in length because of asymmetrical loading which brings more uneven load to the vertebrae and more asymmetrical growth in a vicious cycle (35). But scoliosis can progress very rapidly in some cases, from 25 degrees Cobb angle to 45 degrees in just six months. Such a rapid progression of the curvature can not be attributed only to additional wedging of the vertebrae. Intervertebral discs may be deformed much more rapidly under constant pressure. The role of the ribs is underestimated again. The importance of equal support of the spine through the ribs from both sides had been proved with experiments. Resection of the posterior ends of ribs on one side induced progressive scoliosis in young animals. The spine curved to the side where heads and necks of the ribs had been removed (36). Piggott wrote: »As the operation creates a gap in the bony skeleton along one side of the spine, mechanical pressure from the contralateral intact ribs may push the mobile column over into the gap, and subsequently asymmetrical rib growth may fix and increase the deformity«. He performed rib resection on the concave side of scoliotic patients and concluded »that whereas all curves were progressive before operation there has been but little progression after it, and several curves have shown significant retrogression. It thus appears that operation has had overall a favourable influence...« Such an experiment on patients would not be

approved today and is not reproducible. Sevastik, however, advocates such an operation. According to his theory, ribs on the concave side grow longer because of sympathetic nerve disorder and push vertebrae towards the convex side (37). It is not clear why would such a nerve disorder appear much more frequently on the left side and only after several years of normal development.

When rotation of the vertebrae and rib cage happens, the force of the concave rib to the vertebral body is not opposed by the convex rib anymore, just like in rib resection. The vertebrae lose balanced support from the ribs. Ribs on the concave side push only vertebral bodies toward the convex side and ribs on the convex side direct all their force to the vertebral processes (Fig. 3). Shear forces cause additional turning of the vertebrae and bending of the spine toward the convex side. C. Lehnert-Schroth wrote that in a healthy patient, axially oriented push of the ribs when contracting the intercostal musculature stabilizes the spine, while this push in scoliosis acts unilaterally on the spine and increases the rotation of the vertebrae because the shearing force of the corresponding ribs on the concave side is directed predominantly at the body of the vertebrae, and on the convex side via the costotransversal joint to the spinous processes (17). Roaf showed that the pressure of ribs on spine created a couple of forces tending to increase rotation on a model of distorted rib cage (38). He wrote: »Pressure of ribs on the convex side is posterior to the axis of rotation. Pressure of ribs on the concave side is anterior to the axis of rotation«. With gradual bone remodeling under constant pressure, typical changes in the shape of the ribs and vertebrae evolve. Vertebral bodies are pushed closer to the rib arc on the convex side, narrowing the chest.

The importance of rib symmetry for infantile scoliosis resolution or progression was found by Mehta (39). The difference between left and right rib-vertebral angle at the apex of the curve enabled her to distinguish between resolving and progressive infantile scoliosis. If the difference was less than 20° the spontaneous resolution of scoliosis appeared in 80 percent of cases, if greater than 20° , 80 percent of scoliosis cases progressed.

6. Discussion and conclusions

Sudden onset of scoliosis after several years of normal development can be explained only by a single event as a trigger that leads to the development of the distorted growth. Such an event is a sprain (rotation) of the chest due to bent posture.

Side curvature of the spine is always accompanied by rotation of the rib cage because ribs are connected by the intercostal muscles and cannot spread apart. Tension in the thoracic wall leads to rotation of vertebrae by pulling the ribs at the apex of the curve inwards. This is the only known explanation of the maximal rotation of the vertebrae at the apex of the curve. The axial rotation would be maximal at inflection points if the rotation were produced solely by coupling of the rotation with lateral bending in the intervertebral joints (9). If spines of stillborn babies are dissected free of all muscles, they can be side-bent in the absence of rotation (38).

Bone remodeling is probably more important than primary bone growth in fixing the structural scoliosis. Both are active during growth spurts, but only remodeling proceeds into adulthood when scoliosis may progress further or starts anew. Ribs are deformed in all cases of scoliosis, while vertebrae are not necessarily wedge shaped. Children with pro-

gressive scoliosis may be genetically predisposed for more rapid bone resorption which is regulated by several hormones and their receptors. All hormones known to have an impact on the development of scoliosis affect bone remodeling. An abnormality in the receptors or regulation of any of them would influence the susceptibility for scoliosis. This means that each scoliosis case should be examined individually for its genetic background, a single gene for scoliosis will never be found.

When the vertebrae rotate, the shear forces transmitted by the ribs to the vertebrae turn vertebrae further, and ribs on the concave side push vertebral bodies toward convexity, thus bending the spine. We can prevent the continuous deterioration with a brace (40,41), but braces should act against the rotating forces. If only side push is used to straighten the spine, the rotation will increase and further bending of the spine will follow. Roaf concluded: »Failure to correct rotation invites recurrence. Conversely, even a slight reduction in rotation usually produces a marked cosmetic improvement, often out of all proportion to the radiographic appearances« (38). These findings are taken into account in the construction of newer braces, which allow the regulation in all three planes and stop progression of the curves more ef-

fectively than the old ones. They are also used in Slovenia (42). The use of modern instrumentation has also improved surgical methods of treatment (43).

A properly implemented kinesiotherapeutic exercise program can prevent worsening of the curvature in scoliosis patients and sometimes also the use of a brace. A specific and individualized physiotherapy program is more effective than conventional exercise (44). The Schroth method of physiotherapy for scoliosis is focused on the improvement of the shape of the rib cage by rotational breathing and other exercises (17). Scoliosis-specific exercises can reduce the postural (nonstructural) component of the scoliosis curve that counts up to 9° in children, decrease the chronic asymmetric load on the spine and, in the long run, reduce the risk of progression (45).

Nothing is fundamentally new in the theory of scoliosis initiation and progression presented here. Some ideas are quite old, but in the light of new evidence, it is time for their reconsideration and reevaluation. If unbalanced posture causes scoliosis in children with a neuromuscular disease, it will have the same consequences in healthy children and adolescents who can also adopt bad sitting habits. The most important time for brace wear is thus schooltime, not nighttime.

References

1. Vasiliadis ES, Grivas TB, Kaspiris A. Historical overview of spinal deformities in ancient Greece. *Scoliosis* 2009;4:6.
2. Negrini S, Aulisa AG, Aulisa L, Circo AB, Mauroy JC de, Durmala J, et al. 2011 SOSORT guidelines: Orthopaedic and Rehabilitation treatment of idiopathic scoliosis during growth. *Scoliosis* 2012;7:3.
3. Kouwenhoven JW, Castelein RM. The pathogenesis of adolescent idiopathic scoliosis: review of the literature. *Spine* 2008;33(26):2898-2908.
4. Košak R. Skoliotične deformacije hrbtenice pri otroku (Definicija, delitev, diagnoza). In: Hrbtenica v ortopediji. Zbornik predavanj; VIII. Mariborsko ortopedsko srečanje. Maribor: Univerzitetni klinični center Maribor; 2012. p. 41-44.
5. Cheng JC, Castelein RM, Chu WC, Danielsson AJ, Dobbs MB, Grivas TB, et al. Adolescent idiopathic scoliosis. *Nature Reviews Disease Primers* 2015;1:15030.
6. Schlösser TPC, van der Heijden GJMG, Versteeg AL, Castelein RM. How 'Idiopathic' Is Adolescent Idiopathic Scoliosis? A Systematic Review on Associated Abnormalities. *Plos One* 2014;9(5):e97461.
7. Castelein RM, van Dieën JH, Smit TH. The role of dorsal shear forces in the pathogenesis of adolescent idiopathic scoliosis — a hypothesis. *Med Hypotheses* 2005;65:501-508.

8. Kouwenhoven J-WM, Smit TH, van der Veen AJ, Kingma I, van Dieën JH, Castelein RM. Effects of Dorsal Versus Ventral Shear Loads on the Rotational Stability of the Thoracic Spine. A Biomechanical Porcine and Human Cadaveric Study. *Spine* 2007;32(23):2545–2550.
9. Stokes IAF. Axial Rotation Component of Thoracic Scoliosis. *J Orthopaed Res* 1989;7(5):702–708.
10. Janssen MM, Kouwenhoven JW, Schlösser TP, Viergever MA, Bartels LW, Castelein RM, et al. Analysis of preexistent vertebral rotation in the normal infantile, juvenile, and adolescent spine. *Spine* 2011;36(7):E486–491.
11. Bushell GR, Ghosh P, Taylor TK, Sutherland JM. The Collagen of the Intervertebral Disc in Adolescent Idiopathic Scoliosis. *J Bone Joint Surg Br* 1979;61-B (4):501–508.
12. Shirley ED, DeMaio M, Bodurtha J, Ehlers-Danlos Syndrome in Orthopaedics: Etiology, Diagnosis, and Treatment Implications. *Sports Health* 2012;4(5):394–403.
13. Czaprowski D, Kotwicki T, Pawłowska P, Stoliński L. Joint hypermobility in children with idiopathic scoliosis: SOSORT award 2011 winner. *Scoliosis* 2011;6:22.
14. Guo X, Chau W-W, Chan Y-L, Cheng C-Y. Relative anterior spinal overgrowth in adolescent idiopathic scoliosis. Results of disproportionate endochondral-membranous bone growth. *J Bone Joint Surg Br* 2003;85-B (7):1026–1031.
15. Schlösser TPC, van Stralen M, Chu WCW, Lam T-P, Ng BKW, Vincken KL, et al. Anterior Overgrowth in Primary Curves, Compensatory Curves and Junctional Segments in Adolescent Idiopathic Scoliosis. *Plos One* 2016;11(7):e0160267.
16. Brink RC, Schlösser TP, Colo D, Vavruch L, van Stralen M, Vincken KL, et al. Anterior Spinal Overgrowth is the Result of the Scoliotic Mechanism and is Located in the Disc. *Spine* 2017;42(11):818–822.
17. Lehnert-Schroth C. Three-dimensional treatment for scoliosis. A physiotherapeutic method for deformities of the spine. California: The Martindale Press Palo Alto; 2008.
18. Hawes MC, O'Brien JP. The transformation of spinal curvature into spinal deformity: pathological processes and implications for treatment. *Scoliosis* 2006;1:3.
19. Aronsson DD, Stokes IAF. Nonfusion treatment of adolescent idiopathic scoliosis by growth modulation and remodeling. *J. Pediatr. Orthop.* 2011;31(1 Suppl): S99–106.
20. Day G, Frawley K, Phillips G, McPhee IB, Labrom R, Askin G, et al. The vertebral body growth plate in scoliosis: a primary disturbance of growth? *Scoliosis* 2008;3:3.
21. Stokes IAF, Aronsson DD. Disc and Vertebral Wedging in Patients With Progressive Scoliosis. *J Spinal Disord* 2001;14(4):317–322.
22. Marty-Poumarat C, Scattin L, Marpeau M, Garreau de Loubresse C, Aegerter P. Natural History of Progressive Adult Scoliosis. *Spine* 2007;32(11):1227–1234.
23. Bone Curriculum. Educational resource materials by the American Society for Bone and Mineral Research. *Bone Growth and Remodeling. Growth in long bones*; 2008 [cited 2016 06 11] Available from: <http://depts.washington.edu/bonebio/ASBMRed/growth.html>.
24. Pearson, OM, Lieberman, DE. The Aging of Wolff's "Law": Ontogeny and Responses to Mechanical Loading in Cortical Bone. *Yearb Phys Anthropol* 2004;47:63–99.
25. Acaroglu E, Bobe R, Enouf J, Marcucio R, Moldovan F, Moreau A. The metabolic basis of adolescent idiopathic scoliosis: 2011 report of the "metabolic" workgroup of the Fondation Yves Cotrel. *Eur Spine J* 2012;21:1033–1042.
26. Brodner W, Krepler P, Nicolakis M, Langer M, Kaider A, Lack W, et al. Melatonin and adolescent idiopathic scoliosis. *J Bone Joint Surg Br.* 2000;82(3):399–403.
27. Man GC, Wong JH, Wang WW, Sun GQ, Yeung BH, Ng TB, et al. Abnormal melatonin receptor 1B expression in osteoblasts from girls with adolescent idiopathic scoliosis. *J Pineal Res* 2011;50(4):395–402.
28. Histing T, Anton C, Scheuer C, Garcia P, Holstein JH, Klein M, et al. Melatonin impairs fracture healing by suppressing RANKL-mediated bone remodeling. *J Surg Res* 2012;173(1):83–90.
29. Wu T, Sun X, Zhu Z, Yan H, Guo J, Cheng JC, et al. Role of Enhanced Central Leptin Activity in a Scoliosis Model Created in Bipedal Amputated Mice. *Spine* 2015;40(19):E1041–1045.
30. Yadav VK, Oury F, Suda N, Liu Z-W, Gao X-B, Confavreux C, et al. A Serotonin-Dependent Mechanism Explains the Leptin Regulation of Bone Mass, Appetite, and Energy Expenditure. *Cell* 2009;138(5):976–989.
31. Ishida K, Aota Y, Mitsugi N, Kono M, Higashi T, Kawai T, et al. Relationship between bone density and bone metabolism in adolescent idiopathic scoliosis. *Scoliosis* 2015;10:9.
32. Helenius J, Jalanko H, Remes V, Sairanen H, Salminen S, Holmberg C, et al. Scoliosis After Solid Organ Transplantation in Children and Adolescents. *Am J Transplant* 2006;6(2):324–330.
33. Goldberg C, Dowling FE. Handedness and scoliosis convexity: a reappraisal. *Spine* 1990;15(2):61–64.
34. Werner BC, Skalsky AJ, McDonald CM, Han JJ. Convexity of scoliosis related to handedness in identical twin boys with Duchenne's muscular dystrophy: a case report. *Arch Phys Med Rehabil* 2008;89(10):2021–2024.
35. Modi HN, Suh SW, Song H-R, Yang J-H, Kim H-J, Modi CH. Differential wedging of vertebral body and intervertebral disc in thoracic and lumbar spine in adolescent idiopathic scoliosis – A cross sectional study in 150 patients. *Scoliosis* 2008;3:11.
36. Piggott H. Posterior rib resection in scoliosis. A preliminary report. *J Bone Joint Surg Br* 1973;55 B(4):663–671.
37. Sevastik J, Burwell RG, Dangerfield PH. A new concept for the etiopathogenesis of the thoracospinal deformity of idiopathic scoliosis: summary of an electronic focus group debate of the IBSE. *Eur Spine J* 2003;12(4):440–450.
38. Roaf R. Rotation movements of the spine with special reference to scoliosis. *J Bone Joint Surg Br* 1958;40-B(2):312–332.

39. Mehta MH. The rib-vertebra angle in the early diagnosis between resolving and progressive infantile scoliosis. *J Bone Joint Surg Br* 1972;54-B(2):230-243.
40. Weinstein SL, Dolan LA, Wright JG, Dobbs MB. Effects of Bracing in Adolescents with Idiopathic Scoliosis. *New Engl J Med* 2013;369(16):1512-15.
41. Aulisa AG, Guzzanti V, Marzetti E, Giordano M, Falciglia F, Aulisa L. Brace treatment in juvenile idiopathic scoliosis: a prospective study in accordance with the SRS criteria for bracing studies - SOSORT award 2013 winner. *Scoliosis* 2014;9:3.
42. Hero N. Manj neprijetno zdravljenje skolioze. *Delo* 2014;18. december: 13.
43. Mohar J, Mihalič R, Hero N. Primerjava operativnega zdravljenja skolioz v Ortopedski bolnišnici Valdoltra v letih 1998 in 2008. *Zdrav Vestn Supl* 2009;78: II-66-72.
44. Naglič N. Fizioterapevtski pristopi k zdravljenju pacientov z adolescentno idiopatsko skoliozo in torakalno hiperkifoza. *Rehabilitacija* 2011;10(2):56-64.
45. Negrini A, Parzini S, Negrini MG, Romano M, Atanasio S, Zaina F, Negrini S. Adult scoliosis can be reduced through specific SEAS exercises: a case report. *Scoliosis* 2008;3:20.